


available at www.sciencedirect.com
journal homepage: www.europeanurology.com



European Association of Urology



Platinum Priority – Prostate Cancer

Editorial by XXX on pp. x–y of this issue

High Diagnostic Performance of Short Magnetic Resonance Imaging Protocols for Prostate Cancer Detection in Biopsy-naïve Men: The Next Step in Magnetic Resonance Imaging Accessibility

Marloes van der Leest^{a,†,*}, Bas Israël^{a,b,†}, Erik Bastiaan Cornel^c, Patrik Zámecnik^a, Ivo G. Schoots^d, Hans van der Lelij^e, Anwar R. Padhani^f, Maroeska Rovers^g, Inge van Oort^b, Michiel Sedelaar^b, Christina Hulsbergen-van de Kaa^h, Gerjon Hannink^g, Jeroen Veltman^{i,‡}, Jelle Barentsz^{a,‡}

^a Department of Radiology and Nuclear Medicine, Radboud University Medical Center, Nijmegen, The Netherlands; ^b Department of Urology, Radboud University Medical Center, Nijmegen, The Netherlands; ^c Department of Urology, Ziekenhuis Groep Twente, Almelo-Hengelo, The Netherlands; ^d Department of Radiology and Nuclear Medicine, Erasmus University Medical Center, Rotterdam, The Netherlands; ^e Department of Radiology and Nuclear Medicine, Maastad Hospital, Rotterdam, The Netherlands; ^f Paul Strickland Scanner Centre, Mount Vernon Cancer Centre, Northwood, UK; ^g Department of Operating Rooms, Radboud University Medical Center, Nijmegen, The Netherlands; ^h Laboratory Pathology Oost-Nederland, Hengelo, The Netherlands; ⁱ Department of Radiology, Ziekenhuis Groep Twente, Almelo-Hengelo, The Netherlands

Article info

Article history:

Accepted May 17, 2019

Associate Editor:

James Catto

Keywords:

Abbreviated prostate magnetic resonance imaging protocols
Biparametric magnetic resonance imaging
Diagnostic imaging
Dynamic contrast-enhanced imaging
Prostate cancer
Prostate Imaging Reporting and Data System

Abstract

Background: To make magnetic resonance imaging (MRI) more accessible to men at risk of high-grade prostate cancer (PCa), there is a need for quicker, simpler, and less costly MRI protocols.

Objective: To compare the diagnostic performance of monoplanar (“fast” biparametric MRI [bp-MRI]) and triplanar noncontrast bp-MRI with that of the current contrast-enhanced multiparametric MRI (mp-MRI) in the detection of high-grade PCa in biopsy-naïve men.

Design, setting, and participants: A prospective, multireader, head-to-head study included 626 biopsy-naïve men, between February 2015 and February 2018.

Intervention: Men underwent prebiopsy contrast-enhanced mp-MRI. Prior to biopsy, two blinded expert readers subsequently assessed “fast” bp-MRI, bp-MRI, and mp-MRI. Thereafter, systematic transrectal ultrasound-guided biopsies (SBs) were performed. Men with suspicious mp-MRI (Prostate Imaging Reporting and Data System 3–5 lesions) also underwent MR-in-bore biopsy (MRGB).

Outcome measurements and statistical analysis: Primary outcome was the diagnostic performance of each protocol for the detection of high-grade PCa. Secondary outcomes included the difference in biopsy avoidance, detection of low-grade PCa, acquisition times, decision curve analyses, inter-reader agreement, and direct costs. Results from combined MRGB and SB were used as the reference standard. High-grade PCa was defined as grade ≥ 2 .

Results and limitations: Sensitivity for high-grade PCa for all protocols was 95% (180/190; 95% confidence interval [CI]: 91–97%). Specificity was 65% (285/436; 95% CI: 61–

[†] Marloes van der Leest and Bas Israël are co-first authors.

[‡] Jeroen Veltman and Jelle O. Barentsz are co-senior authors.

* Corresponding author. Department of Radiology and Nuclear Medicine, Radboud University Medical Center, P.O. Box 9101, Nijmegen 6500 HB, The Netherlands. Tel. +31 024 3619196; Fax: +31 024 3540866.

E-mail address: marloes.vanderleest@radboudumc.nl (M. van der Leest).

<https://doi.org/10.1016/j.eururo.2019.05.029>

0302-2838/© 2019 The Authors. Published by Elsevier B.V. on behalf of European Association of Urology. This is an open access article under the CC BY-NC-ND license (<http://creativecommons.org/licenses/by-nc-nd/4.0/>).

Please cite this article in press as: van der Leest M, et al. High Diagnostic Performance of Short Magnetic Resonance Imaging Protocols for Prostate Cancer Detection in Biopsy-naïve Men: The Next Step in Magnetic Resonance Imaging Accessibility. Eur Urol (2019), <https://doi.org/10.1016/j.eururo.2019.05.029>

70%) for “fast” bp-MRI and 69% (299/436; 95% CI: 64–73%) for bp-MRI and mp-MRI. With fast bp-MRI, 0.96% (6/626) more low-grade PCa was detected. Biopsy could be avoided in 47% for the fast bp-MRI and in 49% for the bp-MRI and mp-MRI protocols. Fast bp-MRI and bp-MRI can be performed in 8 and 13 min, respectively, instead of 16 min at lower direct costs. Inter-reader agreement was 90% for fast bp-MRI protocol and 93% for bp-MRI protocol. A main limitation is the generalizability of these results in less experienced centers.

Conclusions: Short MRI protocols can improve prostate MRI accessibility at a lower direct cost. For fast bp-MRI, this is at the cost of ~2% more biopsies and ~1% more over-detection of low-grade PCa. In order to implement this technique in nonexpert, low-volume, lower-field-strength scanners, further prospective studies have to be performed.

Patient summary: We compared the value of three different magnetic resonance imaging (MRI) protocols for the detection of prostate cancer in men with elevated prostate-specific antigen levels. Our results show that, when used in expert centers, shorter MRI protocols do not compromise the detection of harmful disease. This increases MRI capacity at lower direct costs.

© 2019 The Authors. Published by Elsevier B.V. on behalf of European Association of Urology. This is an open access article under the CC BY-NC-ND license (<http://creativecommons.org/licenses/by-nc-nd/4.0/>).

1. Introduction

Multiparametric prostate magnetic resonance imaging (mp-MRI) with subsequent MR-directed biopsy of suspicious lesions has been described to be a useful diagnostic method to detect high-grade prostate cancer (PCa) in men with elevated serum prostate-specific antigen (PSA) levels [1]. Recent studies have shown that mp-MRI can avoid unnecessary prostate biopsy in biopsy-naïve men [2–5]. Furthermore, in comparison with systematic transrectal ultrasound-guided biopsies (SBs), detection rates of low-grade PCa are lower and those of high-grade PCa are similar or higher [2–5].

State-of-the-art full diagnostic mp-MRI of the prostate performed according to the Prostate Imaging Reporting and Data System (PI-RADS) v2 guidelines, consists of T2-weighted imaging (T2WI) in three orthogonal planes, and diffusion-weighted imaging (DWI) and dynamic contrast-enhanced (DCE) imaging after administration of intravenous contrast material [6]. According to the PI-RADS v2 system, the role of DCE imaging is being reserved for the clarification of equivocal abnormalities in the peripheral zone [6]. The full PI-RADS-compliant protocol is, however, time-consuming and costly, and has implementation challenges where MRI accessibility is limited. This may restrict the routine use of MRI as a triage test in men with elevated PSA.

Recent studies suggest that the use of DCE imaging and T2WI in multiple planes does not improve the overall accuracy of MRI [7,8]. Therefore, short, noncontrast biparametric MRI (bp-MRI; ie, T2WI and DWI) has been suggested to reduce examination time and cost, while retaining sufficient diagnostic accuracy to “rule out” high-grade PCa in biopsy-naïve men [9–13]. Furthermore, intravenous access and potential gadolinium-based contrast agent-related toxicities can be prevented [14,15]. Thus, we conducted a multireader, prospective study to investigate the diagnostic performance of currently used mp-MRI versus noncontrast bp-MRI in three planes (bp-MRI) and in one plane (“fast” bp-MRI) to detect high-grade PCa in biopsy-naïve men.

2. Patients and methods

2.1. Study population

This prospective, multicenter study was performed in accordance with institutional review board requirements and was conducted from February 2015 to February 2018. The full study protocol and results have been described previously [2]. All included patients provided written informed consent. Eligible men were aged 50–75 yr with a PSA value of ≥ 3 ng/ml, with no history of prior biopsy. A total of 699 men were referred by general practitioners and were enrolled by urologists from one university center (Radboudumc, Nijmegen, $n = 169$), two community hospitals (Ziekenhuis Groep Twente, $n = 357$, and Maasstad Hospital, Rotterdam, $n = 152$), and one diagnostic center (Andros Men’s Clinic, $n = 21$; Fig. 1).

2.2. MRI examination and image analysis

After written consent, patients underwent mp-MRI examinations on 3 Tesla MRI scanners (Magnetom Skyra; Siemens Healthineers, Erlangen, Germany) with pelvic phased-array coils, according to PI-RADS v2 standards [6].

2.2.1. Multiparametric MRI examination

The mp-MRI protocol consisted of T2WI in three planes, DWI with calculated high b -value images ($b \geq 1400$ s/mm²), and apparent diffusion coefficient (ADC) map and DCE imaging (Supplementary Table 1).

2.2.2. Biparametric MRI and “fast” bp-MRI evaluation

The bp-MRI protocol used the mp-MRI images but without DCE imaging (five image sets). The fast bp-MRI evaluation included only axial T2WI, reconstructed axial ADC map, and high b -value images (three image sets).

2.2.3. MRI assessment

Images were prospectively independently analyzed before biopsy by two highly experienced radiologists: J.B. and M.v.d.L., with 25 and 5 yr of experience with prostate MRI, respectively. Readers were informed about clinical findings (ie, study participation, age, PSA level, and digital rectal examination findings). First, the fast bp-MRI examination was evaluated (Supplementary Fig. 1A–C; fast bp-MRI). The images were assigned to PI-RADS v2 criteria for T2WI and DWI, and a final PI-RADS score was assessed and registered. Thereafter, the readers had the

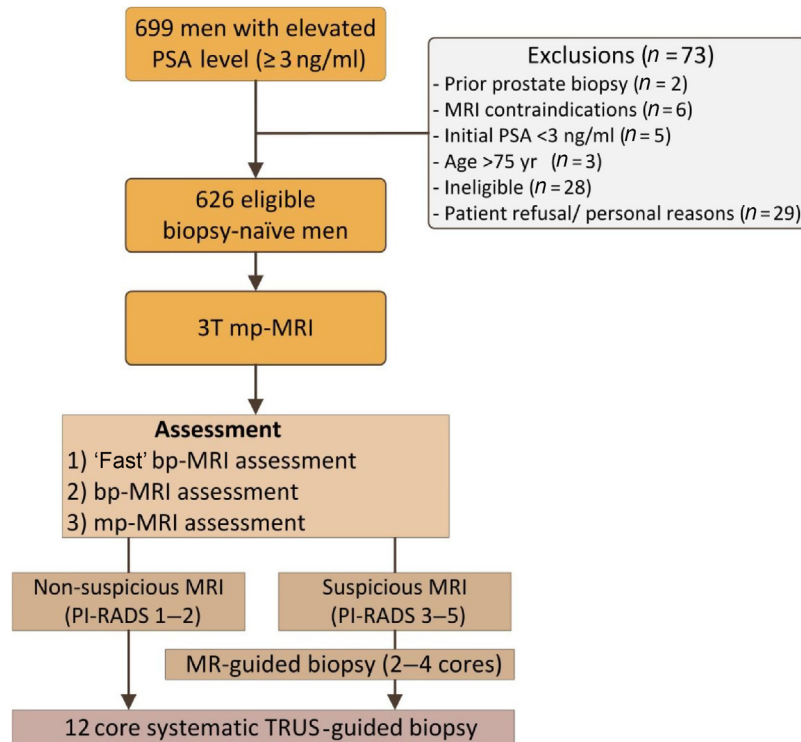


Fig. 1 – Flow diagram of study design, participants, and MRI assessment. bp = biparametric; mp = multiparametric; MRI = magnetic resonance imaging; PI-RADS = Prostate Imaging Reporting and Data System; PSA = prostate-specific antigen; TRUS= transrectal ultrasound.

sagittal and coronal T2WI available and reassessed the final PI-RADS score for bp-MRI. For bp-MRI assessment, peripheral zone lesions scored as PI-RADS 3 could not be “upgraded” to PI-RADS 4 because DCE imaging was not available [6]. After the bp-MRI score was registered (Supplementary Fig. 1A–E; bp-MRI), the DCE images became available, and the final PI-RADS score for the mp-MRI (Supplementary Fig. 1A–F; mp-MRI) was assessed and documented [6]. In case of discordance for the mp-MRI readings between the two radiologists, consensus assessment was used for biopsy decisions. Fast bp-MRI and bp-MRI discordances were assessed 1 yr after study finalization, blinded to consensus mp-MRI score and histopathology, without the possibility of post hoc alterations. MRI findings were classified as suspicious in the presence of a PI-RADS 3–5 lesion and nonsuspicious in case of PI-RADS categories 1–2.

2.3. Systematic and targeted biopsy

Men with PI-RADS 3–5 lesions on the mp-MRI examination underwent a two- to four-core in-bore MR-guided biopsy (MRGB) of each suspicious MRI lesion(s). Then, blinded to the MRI findings, a 12-core SB was performed without additional cores targeting hypoechoic lesions, as described previously [2].

2.4. Histopathological examination and high-grade PCA definition

Biopsies were centrally reviewed by a urologist, blinded to the initial histopathology and MRI results. In case of PCA, the International Society of Urologic Pathology Grade (G) was assigned [16]. High-grade PCA was defined as any cancer core of $G \geq 2$ (Gleason score $\geq 3 + 4$). Results from combined biopsies (MRGB and SB) were used as the reference standard to assess outcomes.

2.5. Outcome measurements

The primary outcome was the diagnostic performance of each protocol to detect high-grade PCA. Secondary outcomes included the number of men avoiding biopsy for the three MRI protocols, low-grade PCA detection rates, and acquisition times per protocol. Decision curve analyses (DCAs) were performed for different protocols. In addition, the inter-reader agreement on the need for biopsy and “interprotocol” agreement (between the three readings) was analyzed. Direct costs per protocol were assessed; costs for MR equipment, contrast consumables, and labor according to the Dutch health care system guidelines were calculated for the three MRI protocols [17,18].

2.6. Statistical analysis

Characteristics were described using medians and interquartile ranges (IQRs) for continuous variables, and numbers with percentages for categorical variables. In case of multiple lesions, the lesion with the highest PI-RADS score was used as the index lesion. We tested differences in sensitivity and specificity between the reference strategy (mp-MRI) and the other strategies with McNemar’s χ^2 test. Differences in negative (NPV) and positive (PPV) predictive values were tested using the weighted generalized score method, as described by Kosinski [19]. Associated 95% bias-corrected and accelerated bootstrapped confidence intervals (CIs) were obtained using 5000 replications. We tested between protocol differences in PI-RADS 3 scores using a Cochran’s Q test followed by pairwise McNemar’s tests. Newcombe CIs for differences of proportions with matched pairs were calculated [20]. DCA for the different MRI protocols, including a conditional PSA density (PSAd)-based biopsy strategy (≥ 0.15 ng/ml/ml) for equivocal (PI-RADS 3) lesions, was performed, using threshold probabilities ranging from 5% to 20% [21–23]. Additional analyses for PSAd cutoffs of ≥ 0.10 and

0.12 ng/ml/ml were performed. Inter-reader agreement and interprotocol agreement were calculated using Gwet’s agreement coefficient (AC) [24]. ACs were interpreted according to the methods described by Landis and Koch (<0, poor; 0–0.20, slight; 0.21–0.40, fair; 0.41–0.60, moderate; 0.61–0.80, substantial; and 0.81–1.00, almost perfect) [25]. Statistical analyses were performed using R (version 3.5.2; R Foundation for Statistical Computing, Vienna, Austria).

3. Results

3.1. Patient characteristics and MRI results

A total of 699 men were prospectively enrolled; 73 men were excluded for various reasons (Fig. 1). The final study population consisted of 626 men with a median age of 65 yr (IQR 59–68). Median PSA level was 6.4 ng/ml (IQR 5.0–8.6). Patients’ demographics, baseline characteristics, and MRI findings are listed in Table 1. Acquisition times for each protocol are provided in Table 2.

The mp-MRI and bp-MRI protocols were scored as nonsuspicious (PI-RADS 1–2) in 309 (49%) men; for the fast bp-MRI, the lesions were nonsuspicious in 295 (47%) men (Supplementary Fig. 2). Equivocal lesions (PI-RADS 3) were scored in 6.4% (40/626), 7.8% (49/626), and 11% (70/626) of men for the mp-MRI, bp-MRI, and fast bp-MRI protocol, respectively. Thus, compared with mp-MRI, bp-MRI and fast

Table 1 – Patient characteristics and PI-RADS assessment per protocol

Characteristics	
Number of patients, n (%)	626 (100)
Median age at biopsy, yr (IQR)	65 (59–68)
1st-degree family history of PCa, n (%)	
Positive	114 (23)
Unknown	1 (0.16)
DRE, n (%)	
Abnormal	176 (28)
Unknown	5 (0.80)
Median PSA, ng/ml (IQR)	6.4 (5.0–8.6)
Median prostate volume, ml (IQR)	56 (41–77)
Median PSAd, ng/ml/ml (IQR)	0.11 (0.08–0.17)
PI-RADS v2 assessment, n (%)	
“Fast” bp-MRI	
1–2	295 (47)
3	70 (11)
4–5	261 (42)
bp-MRI	
1–2	309 (49)
3	49 (7.8)
4–5	268 (43)
mp-MRI	
1–2	309 (49)
3	40 (6.4)
4–5	277 (44)
Combined histology, n (%)	
No cancer/benign	292 (47)
Low-grade PCa	144 (23)
High-grade PCa	190 (30)

bp = biparametric; DRE = digital rectal examination; IQR = interquartile range; mp = multiparametric; MRI = magnetic resonance imaging; PCa = prostate cancer; PSA = prostate-specific antigen; PSAd = prostate-specific antigen density; PI-RADS = Prostate Imaging Reporting and Data System.
Prostate volume was measured on MRI.

Table 2 – Sequence times per protocol (h:min:s)

Sequence	mp-MRI	bp-MRI	“Fast” bp-MRI
T2WI localizers	0:00:51	0:00:51	0:00:26
T2WI localizer (sagittal)	0:00:07	0:00:07	0:00:00
T2WI sagittal	0:02:31	0:02:31	0:00:00
T2WI coronal	0:02:15	0:02:15	0:00:00
T2WI transversal	0:02:33	0:02:33	0:02:33
DWI	0:04:50	0:04:50	0:04:50
DCE imaging	0:02:50	0:00:00	0:00:00
Total sequence time	0:15:57	0:13:07	0:07:49

bp = biparametric; DCE = dynamic contrast enhanced; DWI = diffusion weighted imaging; mp = multiparametric; MRI = magnetic resonance imaging; T2WI = T2-weighted imaging.

bp-MRI had 1.4% (95% CI: 0.23–2.8; *p* = 0.03) and 4.8% (95% CI: 2.9–6.9; *p* < 0.001) more PI-RADS 3 scores. This resulted in 2.2% (14/626) less PI-RADS 1–2 scores for the fast bp-MRI assessment, and 1.4% (9/626) and 2.6% (16/626) fewer PI-RADS 4 scores for the bp-MRI and fast bp-MRI assessments, respectively.

3.1.1. Diagnostic performance

Using combined histopathology as the reference standard, the sensitivity for high-grade PCa was 95% (180/190) for all three protocols. Specificity was lower (3.2% (95% CI 1.0–5.4); *p* < 0.001) for the fast bp-MRI protocol (65% [285/436]) than that for the bp-MRI and mp-MRI protocols (69% [299/436]; Table 3).

Compared with the NPV for high-grade PCa of the bp-MRI and mp-MRI protocols (97% [299/317]), the NPV for the fast bp-MRI (97% [285/295]) was lower (0.15% [95% CI 0.05–0.31]; *p* < 0.001). The PPV for high-grade PCa was lower (2.4% [95% CI 1.1–3.8]; *p* < 0.001) for the fast bp-MRI protocol (54% [180/331]) compared with the bp-MRI and mp-MRI protocols (57% [180/317]).

Owing to PI-RADS 3 instead of PI-RADS 1–2 diagnoses, fast bp-MRI would lead to additional biopsies in 2.2% (14/626) of men. Biopsy of these men would result in six additional low-grade PCa and eight biopsies without PCa. Owing to focal-early enhancement on mp-MRI, PI-RADS 3 lesions were “upgraded” to PI-RADS 4 in nine men. There was, however, no change in biopsy strategy for these men, as all PI-RADS 3 lesions underwent MRGB. An overview of MRI and histopathological results for each MRI protocol per 100 men is presented in Fig. 2.

DCA showed that with biopsy thresholds ranging from 5% to 15%, restricting biopsies to men with suspicious bp-MRI or mp-MRI, had the highest net benefit. At biopsy thresholds ranging from 15% to 20%, a conditional approach using fast bp-MRI with PI-RADS 4–5 or PI-RADS 3 with PSAd ≥0.15 ng/ml/ml showed the highest net benefit (Fig. 3). DCA for other PSAd cutoffs (≥0.10 and ≥0.12 ng/ml/ml) per protocol are described in Supplementary Fig. 3.

Direct cost reduction of the fast bp-MRI and bp-MRI protocols are €143.35 (54%) and €98.95 (37%), respectively, compared with the costs of the mp-MRI protocol (€264.63),

Table 3 – Diagnostic performance per MRI protocol in the detection of high-grade PCa

	Sensitivity % (95% CI)	Specificity % (95% CI)	NPV % (95% CI)	PPV % (95% CI)	LR– (95% CI)	LR+ (95% CI)
mp-MRI	95 (91–97)	69 (64–73)	97 (94–98)	57 (51–62)	0.077 (0.042–0.14)	3.0 (2.6–3.5)
bp-MRI	95 (91–97)	69 (64–73)	97 (94–98)	57 (51–62)	0.077 (0.042–0.14)	3.0 (2.6–3.5)
“Fast” bp-MRI	95 (91–97)	65 (61–70)	97 (94–98)	54 (49–60)	0.081 (0.044–0.15)	2.7 (2.4–3.1)

bp = biparametric; LR– = negative likelihood ratio; LR+ = positive likelihood ratio; mp = multiparametric; MRI = magnetic resonance imaging; NPV = negative predictive value; PPV = positive predictive value.

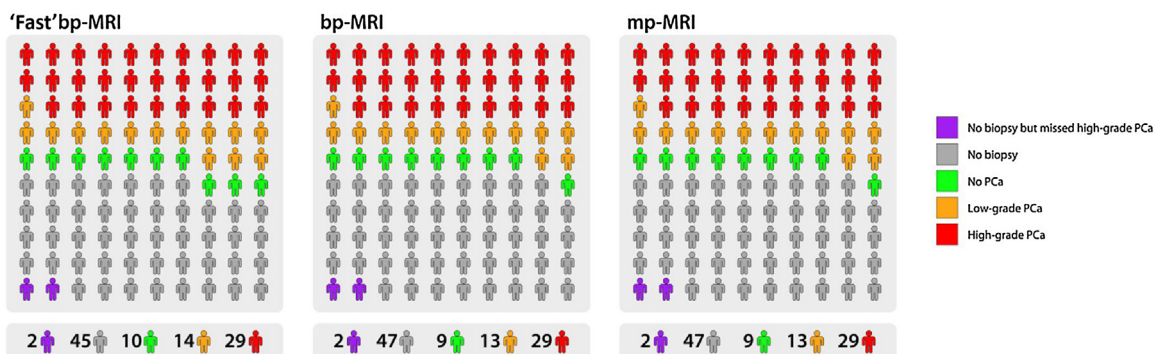


Fig. 2 – MRI and histopathological results for each MRI protocol per 100 men. An overview of results for the three MRI protocols per 100 men, how many biopsies were avoided, and how many low- and high-grade cancers were detected or missed. bp = biparametric; mp = multiparametric; MRI = magnetic resonance imaging; PCa = prostate cancer.

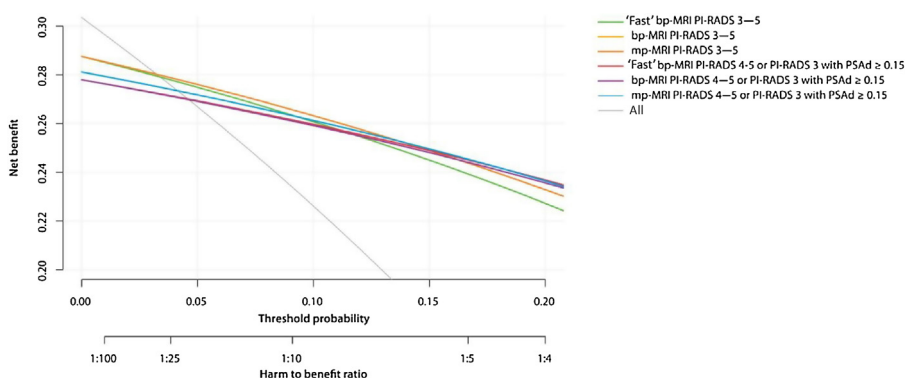


Fig. 3 – Decision curve analysis for the detection of high-grade PCa (PSAd ≥ 0.15 ng/ml/ml). Decision curve analysis using threshold probabilities ranging from 5% to 20% for the three MRI protocols and additional PSAd-based (≥ 0.15 ng/ml/ml) strategies for PI-RADS 3 lesions. The protocol with the highest net benefit regarding high-grade PCa at a specific threshold probability is clinically most useful. Of note, curves of bp-MRI and mp-MRI for PI-RADS 3–5 are equal. DCA showed that with biopsy thresholds ranging from 5% to 15%, restricting biopsies to men with suspicious bp-MRI or mp-MRI produced the highest net benefit. At biopsy thresholds ranging from 15% to 20%, a conditional approach using “fast” bp-MRI with PI-RADS 4–5 or PI-RADS 3 with PSAd ≥ 0.15 ng/ml/ml produced the highest net benefit. Different PSAd cutoffs (≥ 0.10 and > 0.12 ng/ml/ml) are shown in Supplementary Fig. 3. bp = biparametric; mp = multiparametric; DCA = decision curve analysis; MRI = magnetic resonance imaging; PCa = prostate cancer; PI-RADS = Prostate Imaging Reporting and Data System; PSA = prostate-specific antigen; PSAd = PSA density.

according to Dutch healthcare costs. This was particularly because of shorter scanning time costs (Table 4).

3.1.2. Inter-reader agreement

The percent agreement between both readers regarding whether to perform a biopsy (PI-RADS 1–2 vs PI-RADS 3–5) was 90% (Gwet’s AC = 0.81; 95% CI: 0.76–0.85) for fast bp-MRI and 93% (Gwet’s AC = 0.85; 95% CI: 0.81–0.89) for bp-MRI and mp-MRI (Supplementary Table 2). The percent

agreement between the three protocols per PI-RADS category was 94% (Gwet’s AC = 0.92; 95% CI: 0.90–0.94).

4. Discussion

Compared with SB, prostate MRI has multiple advantages in the detection and localization of high-grade PCa in biopsy-naïve men [2–5]. However, limited capacity of scanners and radiologists for prostate MRI and high costs restrict the use

Table 4 – Cost considerations

	Direct MRI costs		
	mp-MRI	bp-MRI	“Fast” bp-MRI
Equipment cost ^a	€108 079.63 (2 scans/h)	€72 413.35 (3 scans/h)	€54 039.81 (4 scans/h)
Contrast consumables ^{a,b}	€23 076.45	€0	€0
Labor cost ^a	€34 502.31	€31 300	€21 878.70
Total MRI costs	€165 658.38	€103 713.34	€75 918.51
Cost per MRI	€264.63	€165.68	€121.28
Cost reduction (%)	–	37	54

bp = biparametric; mp = multiparametric; MRI = magnetic resonance imaging.
^a Dutch cost guidelines and center's reimbursement costs [23,24].
^b Costs for gadolinium-based contrast agent, material, and MRI technologist.

of MRI as a triage test. To our knowledge, this study is the first prospective, multireader, blinded, direct comparison of two different bp-MRI protocols with mp-MRI in biopsy-naïve men.

The present study showed that MRI acquisition time can substantially be reduced with faster, unenhanced bp-MRI protocols while maintaining the advantages of biopsy avoidance without impairing the detection of high-grade PCa. Both bp-MRI protocols had a similar diagnostic performance to that of mp-MRI with respect to “ruling out” high-grade PCa. The use of a fast bp-MRI protocol did not result in decreased detection of high-grade PCa. Even though the NPV of fast bp-MRI was lower than that of bp-MRI and mp-MRI, the difference in NPV between protocols is clinically negligible (0.15% [95% CI 0.05–0.31]), and the NPV of “fast” bp-MRI remains high (97%). This is in agreement with two recent studies that prospectively investigated bp-MRI protocols in biopsy-naïve men according to PI-RADS v2 and reported NPVs of 93% and 96% [9,11]. In contrast to our study, previous bp-MRI studies were either single-reader evaluations, retrospectively conducted or without adherence to the PI-RADS v2 recommendations on image acquisition and readings [6,12].

The noncontrast bp-MRI examination time is approximately 13 min, a reduction of 20% compared with mp-MRI. The fast bp-MRI protocol, without coronal and sagittal T2WI planes, can further reduce the acquisition time to 8 min. Therefore, patient throughput can be doubled to four men per hour. There are, however, diagnostic compromises of the “fast” bp-MRI that have to be considered. It leads to 2.2% (14/626) more biopsies and over-detection of 0.96% (6/626) more low-grade PCa.

Although the exact costs of prostate MRI are highly variable between different centers and countries, the available literature estimates a price range between €230 and €855 for mp-MRI [26–29]. As clinical implementation of fast bp-MRI could save approximately 50%, the total direct costs per MRI examination become €121 in our study. We are aware that direct costs are part of the total costs, and that a gain of direct costs may be reduced by extra costs due to 2.2% more biopsies and detection of 0.96% more low-grade PCa. Future analyses are needed to define the cost-effectiveness of these shorter protocols.

Omitting the coronal and sagittal T2WI planes in “fast” monoplanar bp-MRI makes it more difficult to assign

lesions to the zonal region (peripheral or transition zone), as this is crucial to the determination of the final PI-RADS score. This may explain why there is a 75% increase in PI-RADS 3 “equivocal” cases with fast bp-MRI compared with bp-MRI. This is an indicator of increased diagnostic uncertainty resulting in more unnecessary biopsies. However, compared with Obmann et al. [9] (27%) and Boesen et al. [11] (13%), the percentage of PI-RADS 3 cases in this study for both bp-MRI protocols is rather low (7.8% and 11%). This may be a result of the high-quality image acquisition and expert reading of both bp-MRI studies. This emphasizes the need for high-quality standards in image acquisition and standardized reading. However, even though the percentage of PI-RADS 3 cases of bp-MRI is rather low in this study, it is still higher than that obtained with our mp-MRI (6.4%). This potential diagnostic disadvantage can be reduced by adopting a different biopsy decision strategy: our DCA shows that the highest net benefit can be achieved by restricting biopsies to men with PI-RADS 3 lesions with a PSA of ≥ 0.15 ng/ml/ml.

There are several important features of bp-MRI that facilitate clinical implementation of this technique: (1) intravenous access is not needed, the procedure is completely noninvasive through omitting the contrast media administration, making it suitable also for patients with impaired renal function; (2) patients are not exposed to risks associated with contrast administration, including allergic reactions, intracranial gadolinium deposits, and nephrogenic systemic fibrosis [14,15]; and (3) patients are required to lie motionless during the scan; therefore, a substantial shortening of acquisition time will make the MRI examination more tolerable for patients with claustrophobia and could potentially reduce motion artifacts [30]. A potential disadvantage of implementing fast bp-MRI could be high-grade PCa staging. Although in most cases, this is possible by using high-resolution axial T2WI, a minority of patients may have to undergo an additional MRI examination for better local staging. This is a short (10 min) MRI examination, as it consists only of T2WI in two planes. These planes can be added to the MRGB procedure.

Our study is not without limitations. First, the decision that men need to have MRGB was based on the mp-MRI assessment only. In other words, no MRGB histology was retrieved from additional suspicious bp-MRI lesions, scored as nonsuspicious in the mp-MRI assessment. This will,

however, not negatively affect the detection of high-grade PCa.

Second, our NPV was similar to that reported in other studies comparing nonsuspicious MRI with SB [5,31]. However, the true diagnostic performance cannot be assessed as we neither have the template mapping biopsy, as was performed in the PROMIS study (NPV of 76% for PCa $G \geq 2$) nor the prostatectomy specimen as the gold standard [4].

Third, the two readers involved in our study were expert readers, with an annual caseload of approximately 1000 prostate MRI examinations per year. These readings were performed only centrally, and peripheral readings were not accounted for in this analysis. In addition, the quality of the images obtained using a state-of-the-art 3 T scanner was optimal. Therefore, our results are not directly applicable to other lower-volume nonexpert centers. The almost-perfect agreement between the protocols suggests that PI-RADS v2 is effective as standardized reporting for bp-MRI and mp-MRI. However, previous studies reported moderate-to-high interobserver variability of PI-RADS v2 [32,33]. On the contrary, despite the difference in work experience of both readers (5 vs 25 yr), there was an almost perfect inter-reader agreement for all three MRI protocols. For the clinical implementation of any diagnostic technique, the level of inter-reader variability plays a very important role, reflecting the diagnostic robustness of the technique. Future multicenter studies should investigate the generalizability of inter-reader agreement for community centers.

Finally, the reading of the fast bp-MRI, bp-MRI, and mp-MRI was performed in a set order rather than randomly, which may have introduced a sequential reading bias. However, prostate mp-MRI examinations are read similarly in the “real life”: interpretation usually starts with the reading of the axial DWI and axial T2WI, then using additional planes, and then finally evaluating the DCE images.

5. Conclusions

In this study, both bp-MRI protocols had an equal detection rate of high-grade PCa to mp-MRI. “Fast” bp-MRI can double prostate MRI capacity at lower expenses. This is, however, at the cost of ~2% more biopsies and ~1% more overdiagnosis of low-grade PCa. In order to implement this technique in nonexpert, low-volume, lower-field-strength scanners, further prospective studies have to be performed.

Author contributions: Marloes van der Leest had full access to all the data in the study and takes responsibility for the integrity of the data and the accuracy of the data analysis.

Study concept and design: van der Leest, Rovers, Hulsbergen-van de Kaa, Barentsz.

Acquisition of data: van der Leest, Israël, Cornel, Veltman, van der Lelij, Sedelaar, Hulsbergen-van de Kaa, Barentsz.

Analysis and interpretation of data: van der Leest, Israël, Cornel, Padhani, Hannink, Veltman, Barentsz.

Drafting of the manuscript: van der Leest, Israël, Cornel, Zámečník, Schoots, Padhani, Rovers, Hannink, Veltman, Barentsz.

Critical revision of the manuscript for important intellectual content: van der Leest, Israël, Cornel, Zámečník, Schoots, van der Lelij, Padhani, Rovers, van Oort, Sedelaar, Hulsbergen-van de Kaa, Hannink, Veltman, Barentsz.

Statistical analysis: Hannink.

Obtaining funding: Rovers, Hulsbergen-van de Kaa, Barentsz.

Administrative, technical, or material support: van der Leest, Israël, Cornel, Padhani, Hannink, Veltman, Barentsz.

Supervision: Rovers, Barentsz.

Other: None.

Financial disclosures: Marloes van der Leest certifies that all conflicts of interest, including specific financial interests and relationships and affiliations relevant to the subject matter or materials discussed in the manuscript (eg, employment/affiliation, grants or funding, consultancies, honoraria, stock ownership or options, expert testimony, royalties, or patents filed, received, or pending), are the following: None.

Funding/Support and role of the sponsor: This study was financed by a KWF Kankerbestrijding-Alpe'dHuez grant (KUN 2015-6707) “4 M: Met Prostaat MRI Meer Mans” (Dutch Trial Register under identifier NTR5555) and was also supported by Guerbet (Paris, France).

Acknowledgments: The authors thank the nonacademic urologists for patient enrollment and the radiologists and pathologists for their assessments. They would also like to thank Rianne Hendriks and Martijn Hoogenboom for their contribution.

Appendix A. Supplementary data

Supplementary data associated with this article can be found, in the online version, at <https://doi.org/10.1016/j.eururo.2019.05.029>.

References

- [1] Schoots IG, Roobol MJ, Nieboer D, Bangma CH, Steyerberg EW, Hunink MG. Magnetic resonance imaging-targeted biopsy may enhance the diagnostic accuracy of significant prostate cancer detection compared to standard transrectal ultrasound-guided biopsy: a systematic review and meta-analysis. *Eur Urol* 2015;68:438–50.
- [2] van der Leest M, Cornel E, Israel B, et al. Head-to-head comparison of transrectal ultrasound-guided prostate biopsy versus multiparametric prostate resonance imaging with subsequent magnetic resonance-guided biopsy in biopsy-naïve men with elevated prostate-specific antigen: a large prospective multicenter clinical study. *Eur Urol* 2019;75:570–8.
- [3] Kasivivanathan V, Rannikko AS, Borghi M, et al. MRI-targeted or standard biopsy for prostate-cancer diagnosis. *N Engl J Med* 2018;378:1767–77.
- [4] Ahmed HU, El-Shater Bosaily A, Brown LC, et al. Diagnostic accuracy of multi-parametric MRI and TRUS biopsy in prostate cancer (PROMIS): a paired validating confirmatory study. *Lancet* 2017;389:815–22.
- [5] Rouviere O, Puech P, Renard-Penna R, et al. Use of prostate systematic and targeted biopsy on the basis of multiparametric MRI in biopsy-naïve patients (MRI-FIRST): a prospective, multicentre, paired diagnostic study. *Lancet Oncol* 2019;20:100–9.
- [6] Weinreb JC, Barentsz JO, Choyke PL, et al. PI-RADS Prostate Imaging – Reporting and Data System: 2015, version 2. *Eur Urol* 2016;69:16–40.
- [7] Woo S, Suh CH, Kim SY, Cho JY, Kim SH, Moon MH. Head-to-head comparison between biparametric and multiparametric MRI for the diagnosis of prostate cancer: a systematic review and meta-analysis. *AJR Am J Roentgenol* 2018;211:W226–41.

- [8] Choi MH, Kim CK, Lee YJ, Jung SE. Prebiopsy biparametric MRI for clinically significant prostate cancer detection with PI-RADS version 2: a multicenter study. *AJR Am J Roentgenol* 2019;212:1–8.
- [9] Obmann VC, Pahwa S, Tabayayong W, et al. Diagnostic accuracy of a rapid biparametric MRI protocol for detection of histologically proven prostate cancer. *Urology* 2018;122:133–8.
- [10] Sherrer RL, Glaser ZA, Gordetsky JB, Nix JW, Porter KK, Rais-Bahrami S. Comparison of biparametric MRI to full multiparametric MRI for detection of clinically significant prostate cancer. *Prostate Cancer Prostatic Dis*. In press. <https://doi.org/10.1038/s41391-018-0107-0>.
- [11] Boesen L, Norgaard N, Logager V, et al. Assessment of the diagnostic accuracy of biparametric magnetic resonance imaging for prostate cancer in biopsy-naïve men: the Biparametric MRI for Detection of Prostate Cancer (BIDOC) Study. *JAMA Netw Open* 2018;1:e180219.
- [12] Kuhl CK, Bruhn R, Kramer N, Nebelung S, Heidenreich A, Schrading S. Abbreviated biparametric prostate MR imaging in men with elevated prostate-specific antigen. *Radiology* 2017;285:493–505.
- [13] Niu XK, Chen XH, Chen ZF, Chen L, Li J, Peng T. Diagnostic performance of biparametric MRI for detection of prostate cancer: a systematic review and meta-analysis. *AJR Am J Roentgenol* 2018;211:369–78.
- [14] Ramalho J, Ramalho M, Jay M, Burke LM, Semelka RC. Gadolinium toxicity and treatment. *Magn Reson Imaging* 2016;34:1394–8.
- [15] Gulani V, Calamante F, Shellock FG, Kanal E, Reeder SB. International society for magnetic resonance in M. Gadolinium deposition in the brain: summary of evidence and recommendations. *Lancet Neurol* 2017;16:564–70.
- [16] Epstein JI, Egevad L, Amin MB, et al. The 2014 International Society of Urological Pathology (ISUP) Consensus Conference on Gleason Grading of Prostatic Carcinoma: definition of grading patterns and proposal for a new grading system. *Am J Surg Pathol* 2016;40:244–52.
- [17] Zorginstituut Nederland. Richtlijn voor het uitvoeren van economische evaluaties in de gezondheidszorg. 2016 In: <https://www.zorginstituutnederland.nl/publicaties/publicatie/2016/02/29/richtlijn-voor-hetuitvoeren-van-economische-evaluaties-in-de-gezondheidszorg>
- [18] NZa. Tarievenlijst eerstelijnsdiagnostiek, TB/CU-7078-01.2014. https://puc.overheid.nl/doc/PUC_11854_22.
- [19] Kosinski AS. A weighted generalized score statistic for comparison of predictive values of diagnostic tests. *Stat Med* 2013;32:964–77.
- [20] Newcombe RG. Improved confidence intervals for the difference between binomial proportions based on paired data. *Stat Med* 1998;17:2635–50.
- [21] Venderink W, van Luijelaar A, Bomers JG, et al. Results of targeted biopsy in men with magnetic resonance imaging lesions classified equivocal, likely or highly likely to be clinically significant prostate cancer. *Eur Urol* 2017;73:353–60.
- [22] Vickers AJ, Van Calster B, Steyerberg EW. Net benefit approaches to the evaluation of prediction models, molecular markers, and diagnostic tests. *BMJ* 2016;352:i6.
- [23] Van Calster B, Wynants L, Verbeek JFM, et al. Reporting and interpreting decision curve analysis: a guide for investigators. *Eur Urol* 2018;74:796–804.
- [24] Gwet KL. Computing inter-rater reliability and its variance in the presence of high agreement. *Br J Math Stat Psychol* 2008;61(Pt 1):29–48.
- [25] Landis JR, Koch GG. The measurement of observer agreement for categorical data. *Biometrics* 1977;33:159–74.
- [26] Venderink W, Govers TM, de Rooij M, Futterer JJ, Sedelaar JPM. Cost-effectiveness comparison of imaging-guided prostate biopsy techniques: systematic transrectal ultrasound, direct in-bore MRI, and image fusion. *AJR Am J Roentgenol* 2017;208:1058–63.
- [27] Gordon LG, James R, Tuffaha HW, Lowe A, Yaxley J. Cost-effectiveness analysis of multiparametric MRI with increased active surveillance for low-risk prostate cancer in Australia. *J Magn Reson Imaging* 2017;45:1304–15.
- [28] Barnett CL, Davenport MS, Montgomery JS, Wei JT, Montie JE, Denton BT. Cost-effectiveness of magnetic resonance imaging and targeted fusion biopsy for early detection of prostate cancer. *BJU Int* 2018;122:50–8.
- [29] Department of Health. Reference cost collection: national schedule of reference costs—year 2017–18—NHS trust and NHS foundation trusts. 2018 In: <https://improvement.nhs.uk/resources/reference-costs/#rc1718>
- [30] Thorpe S, Salkovskis PM, Dittner A. Claustrophobia in MRI: the role of cognitions. *Magn Reson Imaging* 2008;26:1081–8.
- [31] Panebianco V, Barchetti G, Simone G, et al. Negative multiparametric magnetic resonance imaging for prostate cancer: what's next? *Eur Urol* 2018;74:48–54.
- [32] Rosenkrantz AB, Ginocchio LA, Cornfeld D, et al. Interobserver reproducibility of the PI-RADS version 2 Lexicon: a multicenter study of six experienced prostate radiologists. *Radiology* 2016;280:793–804.
- [33] Pickersgill NA, Vetter JM, Andriole GL, et al. Accuracy and variability of prostate multiparametric magnetic resonance imaging interpretation using the Prostate Imaging Reporting and Data System: a blinded comparison of radiologists. *Eur Urol Focus*. In press. <https://doi.org/10.1016/j.euf.2018.10.008>.